

# Correction of the High Female Hairline

Alexander L. Ramirez, MD; Kevin H. Ende, MD; Sheldon S. Kabaker, MD

**Objectives:** To review a technique and to make quantitative analyses of the senior author's 20-year experience with his preferred technique to correct the high female hairline.

**Methods:** A retrospective review of 29 female patients who underwent the hairline-lowering procedure performed by the same surgeon (S.S.K.). We analyzed preoperative and postoperative standardized photographs by taking measurements from the medial and lateral canthi to the anterior hairline. Facial height, from the menton to the hairline, was also measured. We calculated mean values and then used a 2-tailed, paired *t* test to evaluate for statistical significance. Patients also underwent evaluation for satisfaction, complications, and aesthetic result. We reevaluated the measurements from the profile view and compared them with the original data.

**Results:** The photographed midfrontal hairline position was vertically lowered on average 1.3 cm in patients who underwent a single-stage procedure ( $P < .001$ ).

In retrospect, the analysis was flawed compared with clinical experience. Therefore, the profile views were evaluated, and the correlating true curvilinear advancement was an average of 2.1 cm. Three complications occurred, including 1 major effluvium, 1 minor effluvium, and 1 scar that required revision. Patient satisfaction was extremely high.

**Conclusions:** Advancement of the female hairline by incorporating an irregular trichophytic incision and a posterior scalp advancement flap is an effective and safe technique that has been used by the senior author for more than 2 decades. The average advancement was 2.1 cm in this study. The technique is immediately effective, well tolerated by patients, and associated with minimal complications. Although it is associated with a potentially visible incision, this technique can be used to make the scar virtually invisible.

*Arch Facial Plast Surg.* 2009;11(2):84-90

**I**N CLASSICAL AESTHETICS, THE FACE can be split into vertical thirds, a characteristic of well-balanced and attractively proportioned faces.<sup>1,2</sup> The female hairline is variable in position. In the ideal situation, the hairline is 5 to 6 cm above the medial brows at the trichion, the point where the scalp slopes from a more horizontal to a more vertical position.<sup>3</sup>

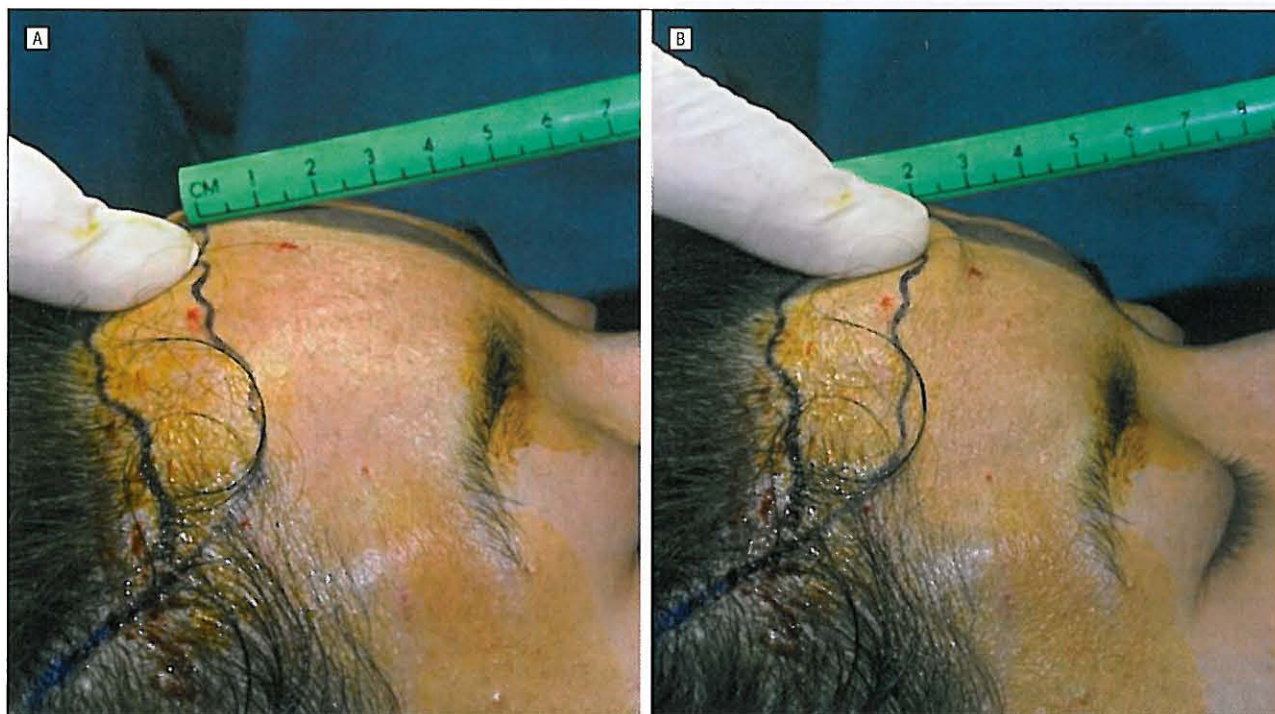
In contrast, a number of women have high hairlines. The primary cause in most of these patients is heredity. These patients have a hairline that is usually stable after puberty without continued recession, and they have adequate density. However, these patients contend that their large forehead and posteriorly displaced hairline make them look masculine, older than their respective years, and less attractive.<sup>4</sup> They are also unhappy because their high hairline limits their hair styling to bangs, which are used as camouflage.<sup>4</sup> Depending on the hair texture and the exit

angle of the hairs, bangs may not always be effective.

In addition, the number of iatrogenic high hairlines is increasing because of the growing popularity of endoscopic browlifts.<sup>2,5</sup> Because the forehead and scalp are moved posteriorly as a unit in an effort to raise the brows, the position of the anterior hairline is often significantly elevated.<sup>6</sup> Despite having a good brow position, these patients continue to have facial disharmony because of their disproportionately large foreheads and their disrupted aesthetic vertical thirds.<sup>4</sup> It is our observation that, in many of these cases, the forehead skin stretches and the hairline is raised a greater distance than the brow is elevated.

Women with high hairlines of iatrogenic or hereditary causes may seek treatment. In this study, we review the senior author's experience (S.S.K.) in addressing this situation. We present his current technique for correcting the high female

**Author Affiliations:** Aesthetic Facial Plastic Surgery Medical Clinic, Oakland, California (Drs Ende and Kabaker); and Division of Facial Plastic Surgery (Dr Kabaker), Department of Otolaryngology–Head and Neck Surgery (Dr Ende), University of California, San Francisco. Dr Ramirez is in private practice in Honolulu, Hawaii.



**Figure 1.** Preoperative evaluation for adequate scalp laxity. A, To determine adequate scalp flexibility, a point is chosen below the hairline and pushed as high as possible. This point of the fingertip is set to 0 at the hairline. B, The fingertip is then pushed as far downward as possible and a measurement is taken. Two centimeters of excursion typically allows for 2 cm of hairline advancement.

hairline, and we evaluate its effectiveness and safety in treating these patients.

## METHODS

We retrospectively analyzed 29 of 74 female patients from January 3, 2000, to November 2007 who underwent a 1-stage (no scalp expansion) hairline-lowering procedure in the senior author's private practice (S.S.K.). Patients underwent preoperative evaluation with a history and physical examination, with specific evaluation of the hairline position for ongoing hair loss, scalp laxity, and a history of previous forehead or scalp procedures such as coronal or endoscopic brow-lift. Patients who had previous coronal brow-lifts or ongoing alopecia were not offered this procedure and were excluded from this study. Patients undergoing hairline advancement with scalp expansion or concomitant browplasty were also excluded. The 29 patients were chosen on the basis of availability of the preoperative and 1-month postoperative digital photographs.

All patients included in the study had standardized digital photographs taken by the physicians to ensure that the Frankfort horizontal plane was respected. The photographs were archived into Mirror Suite software (Canfield Imaging Systems, Fairfield, New Jersey) and analyzed using United Imaging software (United Imaging Inc, Winston-Salem, North Carolina). To obtain objective values on hairline position, we evaluated anterior-posterior and left and right three-quarter photographs. Measurements were taken in an absolute vertical orientation, and the numbers were generated from the right lateral canthus, right medial canthus, left medial canthus, and left lateral canthus to the anterior hairline. Given that all photographs were taken with the patient in repose, respecting the Frankfort plane, we believed that these positions would be the most static and give us a value that could be used to evaluate the anterior hairline position preoperatively and postoperatively. Facial height was also measured per patient from the an-

terior-posterior photograph. This was defined as the point from the menton to the anterior hairline in the midline in an absolute vertical orientation. Numbers were generated from photographs, and then data were recorded into a spreadsheet (Microsoft Excel software; Microsoft Corp, Redmond, Washington). We obtained mean values per patient and then used a 2-tailed, paired *t* test to evaluate preoperative and postoperative averages for statistical significance in the change of hairline position as measured from the change in facial height.

Because the initial analysis did not reflect the true advancement of the hair-bearing scalp over the curvilinear skull, we performed an additional analysis. Lateral photographs taken preoperatively and postoperatively were aligned on the Mirror Suite software. The analysis was performed using the layout board feature to align the glabella, pupils, subnasale, and stomion to ensure appropriate magnification. After printing the images, we used a flexible tape measure to determine the distance from the glabella to the trichion preoperatively and postoperatively and expressed the result as a percentage change.

## PREOPERATIVE EVALUATION

Preoperative evaluation for hair direction, frontotemporal points and recessions, and adequate scalp laxity was crucial in selecting suitable candidates and counseling them. Tight scalps could have only limited lowering without scalp (tissue) expansion. To determine adequate scalp flexibility during the preoperative consultation, a point is chosen below the hairline and pushed as high as possible (**Figure 1**). This point of the fingertip is set to 0 at the hairline. The fingertip is then pushed as far downward as possible and a measurement is taken. For example, 2 cm (average scalp laxity) of excursion typically allows for 2 cm of hairline advancement.

Patients with a cowlick are told that the scar at the edge of posterior growing hair will likely require hair transplants with fine follicular unit grafts for optimal results. The same is true



for those wanting filling of deep temporal recessions or forward advancement of the acutely downward-growing temporal hairs. The risks and potential complications of the procedure are discussed with the patients, including telogen effluvium, visible or widened scar, bleeding, infection, the need for further scar camouflage through hair grafting or scar revision, and potential visibility of the scar with future hair loss. All patients are told to expect 6 to 12 months of diminished sensation of the frontal scalp.

First, an irregularly irregular trichophytic incision is marked in the anterior hairline for the eventual trichophytic incision. We have found it is helpful at the time of drawing the initial incision to draw parallel markings at 5-mm intervals down the forehead. Laterally, the marking fades posteriorly as the temporal recessions are approached bilaterally. Within the temporal hair, the marking extends backward and then downward for about 2 cm. We try not to mark an incision that transects the posterior branch of the superficial temporal artery. Within the temporal hair, the incision is made parallel to the hairs.

### OPERATIVE TECHNIQUE

After oral premedication, the patient is taken to the operating room and given intravenous sedation, followed by local anesthetic nerve blocks and tumescence injection. This trichophytic incision is made within the fine hairs of the anterior hairline.<sup>3,7,8</sup> This is not a pretrichial incision, as the beveling is critical and is made at about 90° to the exiting hairs. This allows hair growth through the scar and ensures future camouflage (**Figure 2** and **Figure 3**). The beveling is only through the initial 2 to 3 hairs behind the point where there is a transition from fine lanugo-type hair to the thicker and denser frontal hair follicular units. The incision is carried down through the galea transecting the supraorbital and supratrochlear nerve branches and vessels. With tumescence, there is minimal bleeding. Extensive undermining in the subgaleal plane to the nuchal ridge is performed. This is a bloodless plane and is developed quickly. Galeotomies can be performed if needed for greater advancement.<sup>9</sup> These should be created with a depth-controlled No. 15 blade. As a general rule, each galeotomy will add 1 to 2 mm of advancement. Often, several parallel galeotomies may be needed.<sup>4</sup> The depth of the galeotomies should be only to the point where some fat is seen. This is the point where maximum advancement will be obtained from each galeotomy but where the blood supply to the flap, which is just superficial, will not be compromised. Anteriorly, the forehead skin is undermined in the same subgaleal plane, 1 to 2 cm past the marked desired hairline. A complete forehead flap is developed only if a concomitant brow-lift is to be performed. If this is the case, then upward advancement of the forehead flap can be performed in the standard fashion for a brow-lift and fixed to the skull at the desired level.

The scalp flap is then advanced, and the amount of overlap is determined with the D'Assumpção clamp or a similar flap-marking device. Once it is determined how much the scalp can be advanced, an incision is made along one of the premarked lines. This incision is made with a matching bevel to the original trichophytic incision. Non-hair-bearing forehead skin, including the galea/frontalis, is then excised. Two paramedian fixation devices (Endotine; Coapt, Palo Alto, California) are placed in the skull at about 2 to 3 cm above the new hairline; however, if a single Endotine is used, an exact sagittal location is avoided. The devices are placed in a reverse direction to their usual placement with brow-lifting, and two 5-prong retractors are used to provide tissue creep for several minutes before engaging the scalp flap onto the devices. The wound is then closed

in layers using 4-0 and 2-0 polydioxanone sutures to reapproximate the galea and to avoid placing tension on the skin closure. Meticulous attention is paid to the skin closure, often using magnification to ensure proper overlap of the beveled forehead skin over the denuded hair follicles from the trichophytic incision.

### RESULTS

Twenty-nine women who sought treatment for a high hairline were included in the study. Their ages ranged from 21 to 65 years, with an average age of 28 years. The women displayed a range of ethnic backgrounds, including 20 who were white (69%), 6 Asian (21%), 2 African American (7%), and 1 Hispanic (3%). Two patients had a history of endoscopic brow-lift with posterior displacement of their hairline, leading to their interest in advancing the hairline. Patients were followed up from 1 month to 8 years.

The average curvilinear measurement of the hairline was 7.6 cm above the level of the glabella preoperatively and 5.5 cm postoperatively. The computer-studied vertical hairline measurement changed an average of 1.3 cm (a 14.6% change) after the procedure, and this change was statistically significant ( $P < .001$ ) (**Figures 4, 5, 6, and 7**). The average facial height was 19.9 cm preoperatively, and this changed to 18.6 cm postoperatively. When the amount of curvilinear advancement was measured from the profile view, the percentage change was 23%. The correlating true curvilinear hairline advancement based on the profile view was 2.1 cm (thus, the 23% decrease in distance from the hairline to glabella).

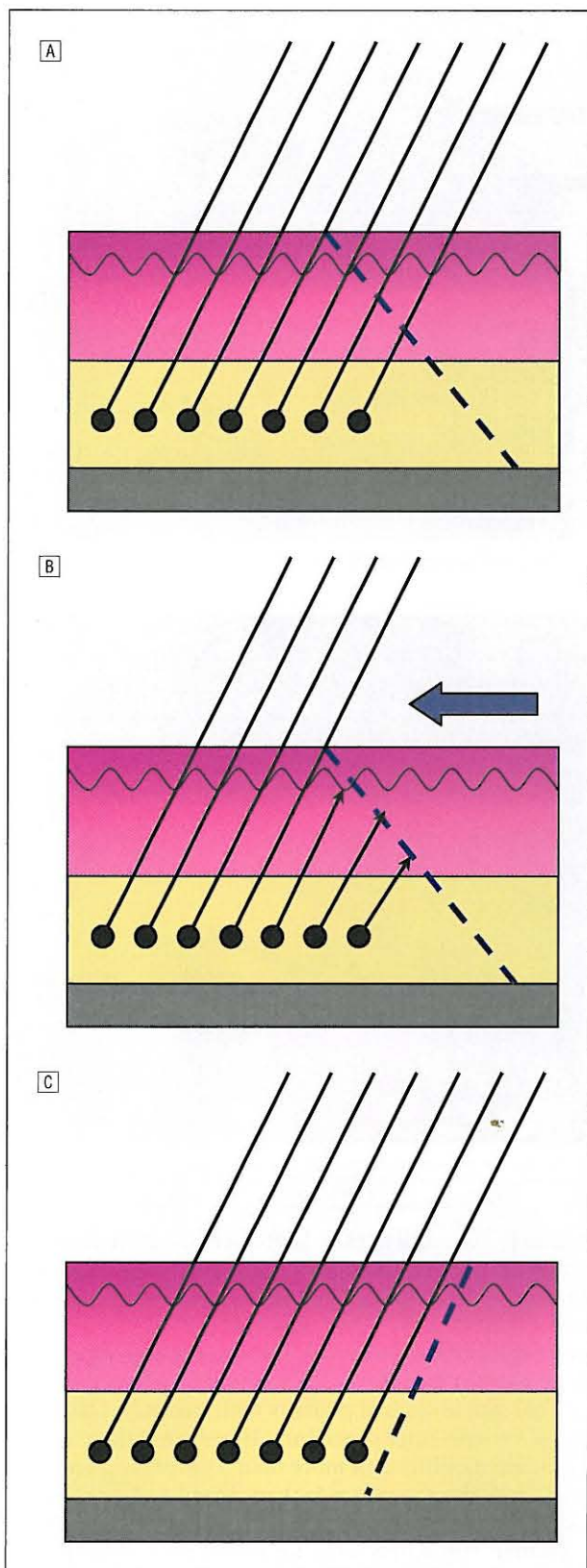
Complications were minimal. One patient had a major effluvium (shock hair loss) after the procedure that resulted in inadequate camouflage for 5 months. Three patients had a minor effluvium, but the area of hair loss and the incision were covered by surrounding hair without difficulties. One patient had a readily identifiable portion of the scar. This patient underwent scar revision with an excellent cosmetic result. All patients had 6 to 12 months of hypoesthesia of the frontal scalp. Three patients underwent follicular unit grafting at a later date to camouflage the scar. These 3 patients had cowlick formation that negated the effect of the trichophytic incision on those hairs that grew posteriorly or posterolaterally.

### COMMENT

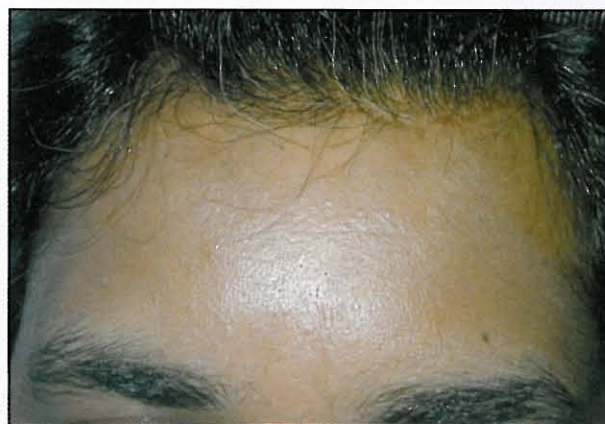Much attention on rejuvenation of the upper third of the face has focused on the position of the brows and the dynamic rhytids. As a result, the position of the anterior hairline is often overlooked or ignored. Despite this, women with high hairlines will seek treatment because their large forehead makes them look more masculine and older than their years, and they lack facial harmony because of their unbalanced vertical thirds.<sup>4</sup> This hairline advancement procedure is an effective and safe technique to correct the high female hairline in these patients.

We were able to measure an average of 1.3 cm of hairline lowering using this computer study in patients with average scalp laxity based on anterior views. This number





**Figure 2.** Illustration of the details of a trichophytic vs a pretrichial incision. A, The dotted line denotes the skin incision for a trichophytic incision. The incision is placed 4 to 5 mm posterior to the hairline and is beveled to include the most anterior 2 to 3 follicular units. B, After removal of excess skin from the forehead flap, it is advanced with a bevel matching the scalp flap. This allows hair growth through the forehead flap from preserved hair follicles and future disguise of the incision. C, A pretrichial incision is made parallel to the hair shafts, with a notable difference from the incision in part A.

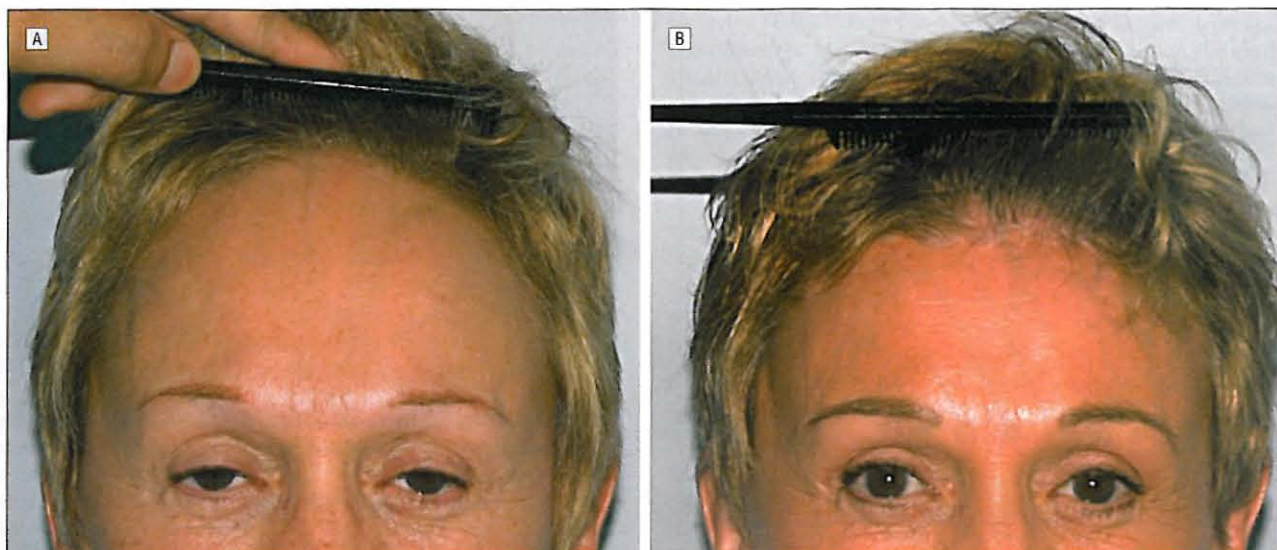

**Figure 3.** Photograph showing detail of the trichophytic incision 1 year after the procedure.

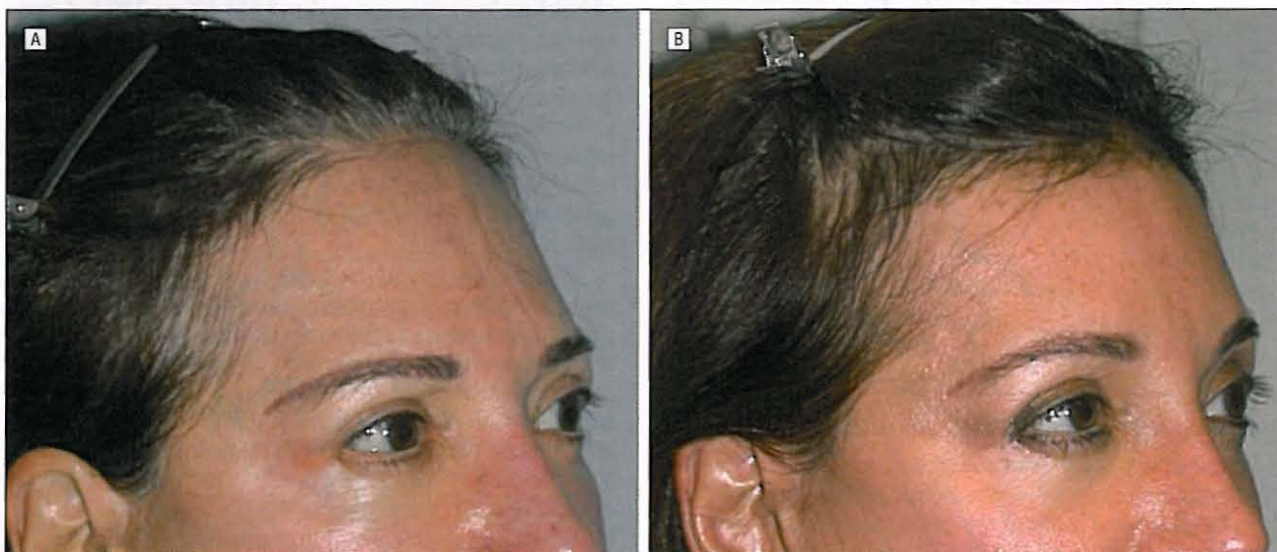
does not reflect the amount of true advancement because it does not take the forehead curvature into account. As a result, we analyzed the profile view, and a greater degree of hairline lowering was realized (14.6% vs 23%). A percentage change of 23% or 2.1 cm is closer to the average advancement that is typically achieved at the time of surgery (range, 1.4-3.0 cm). The procedure was associated with no serious long-term complications, and all of the patients were extremely satisfied with the final cosmetic outcome and scar, even as far as 10 years postoperatively. All patients had hypoesthesia of the frontal scalp for 6 to 12 months after surgery.

Because this technique relies on an incision at the anterior hairline, it is critical to distinguish between a trichophytic and a pretrichial incision.<sup>10</sup> The terms are confusing and often mistakenly used interchangeably.<sup>11</sup> The trichophytic incision, first described by Mayer and Fleming,<sup>7,8</sup> is made within the fine hairs of the anterior hairline and is made perpendicular to the anterior growing hair.<sup>12</sup> The beveling is critical (Figure 2). The hair shaft will be cut just beneath the surface of the epidermis, and the hair bulbs will be left intact and untraumatized. Over time, as hairs begin to grow through the scar and as the hairs grow longer, future coverage and camouflage of the scar result.<sup>1,2,4,5</sup> If the incision is beveled too steeply, then too many hairs are transected and there is a higher chance of hairs getting trapped under the skin, leading to more cyst development postoperatively. The bevel within the temporal hair changes to parallel the hair follicles. This change prevents injury to the hair follicles and gently curves inferiorly at its distal end to lessen standing cone deformities.<sup>5,10</sup> Cowlick formation may make the trichophytic incision less effective on the areas where hair growth is directed posteriorly or laterally. The hairline does not start abruptly, so the incision starts just anterior to the point where there is a consistent density of follicular units.<sup>4,5</sup> We enhance the invisibility of this incision by making it in an irregularly irregular nonrepeating pattern. The unpredictable undulations within the hairline further blend it and disguise it from the discerning eye, and the incision becomes virtually invisible<sup>1,4,5,7</sup> (Figure 3). Exaggerated zig-zag incisions should be avoided. The scar, which could become a criticism or a limitation of this procedure, becomes minimized.





**Figure 4.** Preoperative photograph (A) and postoperative photograph taken 3 years after the hairline-lowering procedure (B) in a study patient.



**Figure 5.** Preoperative photograph (A) and postoperative photograph taken 2 years after the hairline-lowering procedure (B) in a study patient.

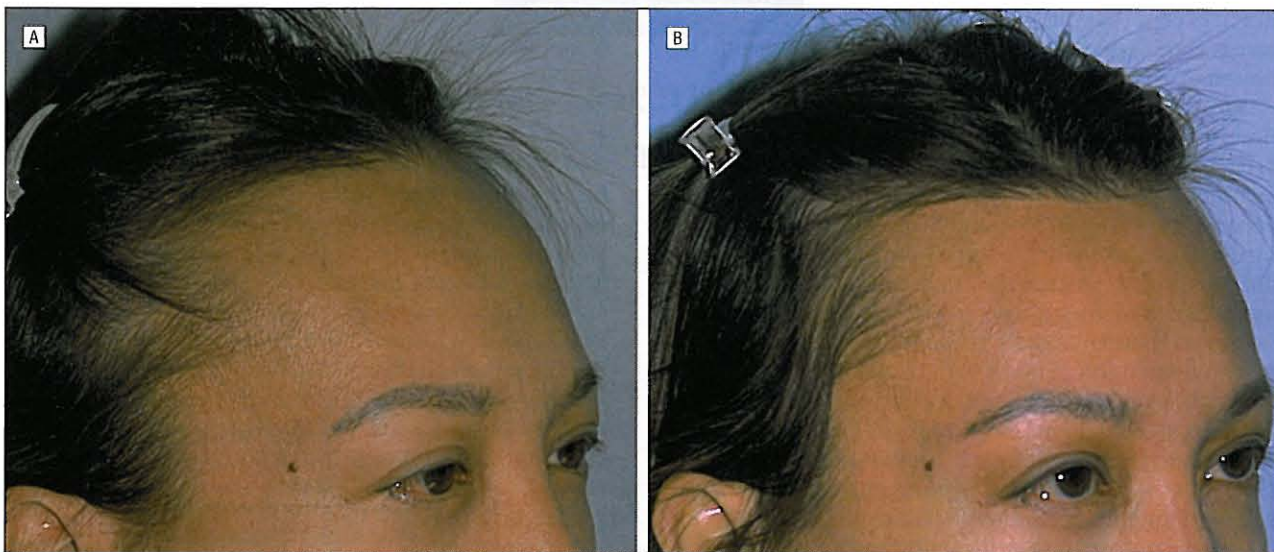
In contrast, a pretrichial incision is made parallel to the growth of the hair<sup>3</sup> (Figure 2). Hair shafts are not cut and hair length is undisturbed. Although this incision may be used at the hairline or within the hairs of the scalp, this incision often becomes more easily identified over time because it is seen as a linear scar with hair behind it. The pretrichial scar is often made more visible because of exposure to the sun<sup>8</sup> (Figure 8). When used at the anterior hairline, a pretrichial incision would require bangs for coverage. Because the goal of the procedure in patients with high hairlines is to enhance the hair styling options so that bangs are not always required, this would be less than ideal. A properly executed irregular trichophytic incision can help achieve this goal.

The pretemporal incision as performed by Guyuron and Rowe,<sup>9</sup> with a trichophytic hairline incision, preserves more of the superficial temporal blood supply to the flap and advances the temporal hairline but has its

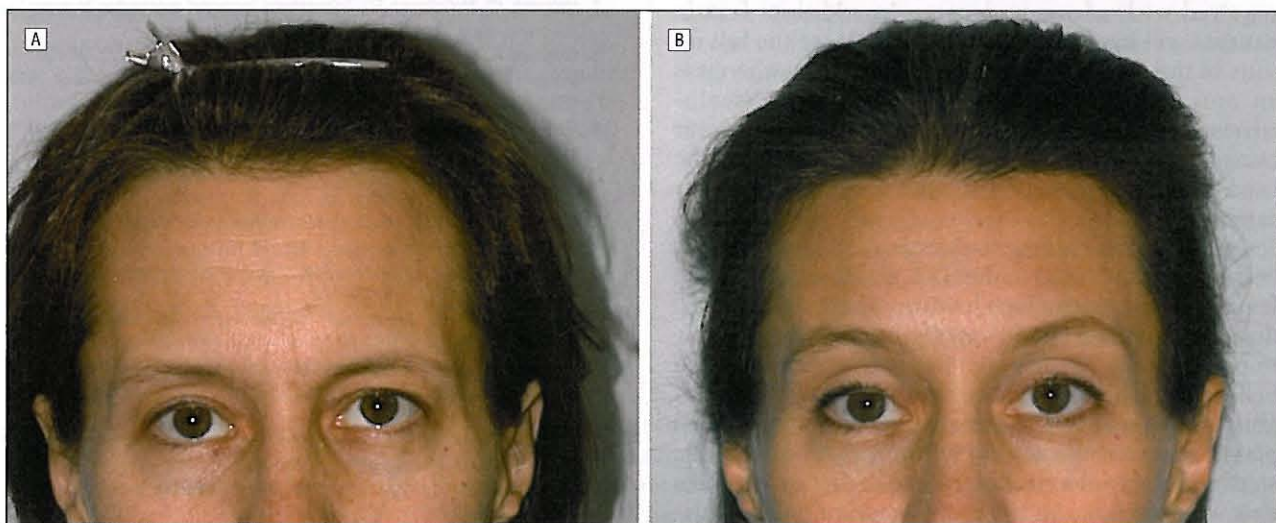aesthetic consequences.<sup>11</sup> Therefore, we turn our incision within the temporal hair and perform follicular unit hair transplants to the temples or temporal recessions when indicated. We thus advocate hair grafting to advance the acutely downward and posteriorly growing temporal hair for maximum cosmesis.

This article studied patients with adequate scalp laxity for a single-stage procedure. However, if there is limited scalp mobility or if more than 3 cm of advancement is needed, the procedure is then staged and a subgaleal tissue expander is used. A round, 14- to 15-cm balloon expander, commonly used for breast reconstruction, is placed during the first stage.<sup>13</sup> Typically, an incision is made in front of the existing hairline, and a subgaleal pocket is developed toward the crown. The pocket should be sufficiently large to accommodate the expander and allow for some movement while the expander repositions itself during the initial injections. Galeotomies can be made to allow for more rapid expansion.<sup>12</sup> The injec-

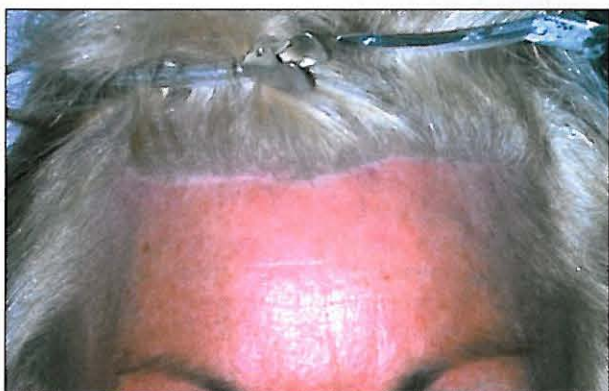



**Figure 6.** Preoperative photograph (A) and postoperative photograph taken 4 years after the hairline-lowering procedure (B) in a study patient.



**Figure 7.** Preoperative photograph (A) and postoperative photograph taken 2½ years after a hairline-lowering procedure with a brow-lift (B).



**Figure 8.** Photograph of a pretrichial incision 1 year after the procedure.

tion port is placed in the temporal area so that it can be easily found during the weekly injections. The incision is then closed in 2 layers. Approximately 100 mL is injected into the expander at the end of the case. This allows the expander to unroll any curled edges that oc-

curred during placement and allows for palpation and localization of the expander.

A permanent suture is placed in the occipital area, posterior and caudal to the implant. This serves as a marker so that measurements can be made from the marker, over the implant, to the anterior hairline to determine the amount of extra scalp obtained from the expansion. This distance is measured and recorded during the weekly expansion to help determine when sufficient extra scalp has been obtained. Starting 10 to 14 days after insertion, the expander is inflated over the course of 6 to 12 weeks. Approximately 100 mL of isotonic sodium chloride solution is injected per week (2-3 times), as tolerated by the patient. Balloon expanders in the scalp are very well tolerated, and the cosmetic inconvenience of the expander is usually limited to the last few weeks. The hairline advancement, which has been up to 18 cm in the senior author's experience in reconstructive cases, occurs during the second stage once sufficient expansion has been achieved.<sup>13</sup> The technique is the same as previously out-

lined, except that the expander is removed initially and care is taken to excise the insertion incision scar with the non-hair-bearing forehead skin.

Ptotic brows could also be easily managed at the same time as the hairline advancement<sup>14</sup> (Figure 7). The approach is similar to that of standard open brow-lifting techniques.<sup>15</sup> On the other hand, 2 patients who had undergone previous endoscopic brow-lifting with resulting elevation of their hairlines were also excellent candidates for this procedure. Despite their brows being in a good position, they did not like the change in their hairlines, and their enlarged foreheads became an issue that required attention (Figure 4).

Other surgical options exist for patients with high hairlines. Hair transplantation using a follicular unit grafting technique is an effective treatment that has a low incidence of complications and is considered the gold standard for hair work. However, this technique is labor intensive, is time consuming, and can be expensive, especially because these patients would require multiple sessions to achieve the significant hairline lowering required with adequate density. In addition, female patients will have to wait 2 to 4 years to see the full results of the transplantation. We believe that, when it is an option, the described hairline-lowering/scalp-advancement procedure has substantial advantages over transplantation. However, follicular unit grafting can be used as a complement to this procedure for further scar camouflage.

In conclusion, we describe herein a technique that has been used by the senior author (S.S.K.) effectively to treat female patients with a high hairline. The technique produces outstanding results rapidly, is readily acceptable to patients, and has few significant complications. We believe the hairline advancement technique is a valuable tool to add to the armamentarium of the facial plastic surgeon. We attempted to perform a scientific statistical study of a clinical technique that gave us data that we hope have added to information on this relatively rare but gratifying procedure for the patient and the surgeon.

Accepted for Publication: August 28, 2008.

Correspondence: Sheldon S. Kabaker, MD, Aesthetic Facial Plastic Surgery Medical Clinic, 3324 Webster St,

Oakland, CA 94609 (Hairflapmd@aol.com or Kevinende@comcast.net).

**Author Contributions:** Study concept and design: Ramirez, Ende, and Kabaker. Acquisition of data: Ramirez, Ende, and Kabaker. Analysis and interpretation of data: Ramirez, Ende, and Kabaker. Drafting of the manuscript: Ramirez, Ende, and Kabaker. Critical revision of the manuscript for important intellectual content: Ramirez, Ende, and Kabaker. Statistical analysis: Ramirez, Ende, and Kabaker. Administrative, technical, and material support: Ramirez, Ende, and Kabaker. Study supervision: Kabaker.

**Financial Disclosure:** None reported.

**Previous Presentation:** This Facial Plastic Surgery Fellowship paper was presented at the American Academy of Facial Plastic Surgery Fall Meeting, September 25, 2005; Oakland, California.

## REFERENCES

1. Guyuron B, Behmand RA, Green R. Shortening of the long forehead. *Plast Reconstr Surg*. 1999;103(1):218-223.
2. Holcomb JD, McCollough EG. Trichophytic incisional approaches to upper facial rejuvenation. *Arch Facial Plast Surg*. 2001;3(1):48-53.
3. Camirand A. Hairline incisions. *Plast Reconstr Surg*. 1999;103(2):736-737.
4. Marten TJ. Hairline lowering during foreheadplasty. *Plast Reconstr Surg*. 1999;103(1):224-236.
5. Owsley TG. Subcutaneous trichophytic forehead browlift: the case for an "open" approach. *J Oral Maxillofac Surg*. 2006;64(7):1133-1136.
6. Griffin JE Jr, Owsley TG. Management of forehead and brow deformities. *Atlas Oral Maxillofac Surg Clin North Am*. 2004;12(2):235-251.
7. Mayer TG, Fleming RW. *Aesthetic and Reconstructive Surgery of the Scalp*. St Louis, MO: Mosby-Year Book Inc; 1992:121-124.
8. Mayer TG, Fleming RW. Hairline aesthetics and styling in hair replacement surgery. *Head Neck Surg*. 1985;7(4):286-302.
9. Guyuron B, Rowe DJ. How to make a long forehead more aesthetic. *Aesthet Surg J*. 2008;28(1):46-50.
10. Camirand A, Doucet J. A comparison between parallel hairline incisions and perpendicular incisions when performing a face lift. *Plast Reconstr Surg*. 1997;99(1):10-15.
11. Vogel JE, Hoopes JE. The subcutaneous forehead lift with an anterior hairline incision. *Ann Plast Surg*. 1992;28(3):257-265.
12. Kabaker SS. Juri flap procedure for the treatment of baldness: two-year experience. *Arch Otolaryngol*. 1979;105(9):509-514.
13. Kabaker SS, Kridel RW, Krugman ME, Swenson RW. Tissue expansion in the treatment of alopecia. *Arch Otolaryngol Head Neck Surg*. 1986;112(7):720-725.
14. Sidle DM, Loos BM, Ramirez AL, Kabaker SS, Maas CS. Use of BioGlue surgical adhesive for brow fixation in endoscopic browplasty. *Arch Facial Plast Surg*. 2005;7(6):393-397.
15. Blackwell KE, Rawnsley JD. Aesthetic considerations in scalp reconstruction. *Facial Plast Surg*. 2008;24(1):11-21.